

Clinical Consensus Statement: Ankyloglossia in Children

Anna H. Messner, MD¹, Jonathan Walsh, MD²,
 Richard M. Rosenfeld, MD, MPH, MBA³, Seth R. Schwartz, MD, MPH⁴,
 Stacey L. Ishman, MD, MPH⁵, Cristina Baldassari, MD⁶,
 Scott E. Brietzke, MD, MPH⁷, David H. Darrow, MD, DDS⁶,
 Nira Goldstein, MD, MPH³, Jessica Levi, MD⁸, Anna K. Meyer, MD⁹,
 Sanjay Parikh, MD¹⁰, Jeffrey P. Simons, MD¹¹,
 Daniel L. Wohl, MD¹², Erin Lambie, MS, MPH¹³, and
 Lisa Satterfield, MS, MPH, CCC-A¹³

Otolaryngology–
 Head and Neck Surgery
 2020, Vol. 162(5) 597–611
 © American Academy of
 Otolaryngology–Head and Neck
 Surgery Foundation 2020
 Reprints and permission:
 sagepub.com/journalsPermissions.nav
 DOI: 10.1177/0194599820915457
 http://otojournal.org



Abstract

Objective. To identify and seek consensus on issues and controversies related to ankyloglossia and upper lip tie in children by using established methodology for American Academy of Otolaryngology–Head and Neck Surgery clinical consensus statements.

Methods. An expert panel of pediatric otolaryngologists was assembled with nominated representatives of otolaryngology organizations. The target population was children aged 0 to 18 years, including breastfeeding infants. A modified Delphi method was used to distill expert opinion into clinical statements that met a standardized definition of consensus, per established methodology published by the American Academy of Otolaryngology–Head and Neck Surgery.

Results. After 3 iterative Delphi method surveys of 89 total statements, 41 met the predefined criteria for consensus, 17 were near consensus, and 28 did not reach consensus. The clinical statements were grouped into several categories for the purposes of presentation and discussion: ankyloglossia (general), buccal tie, ankyloglossia and sleep apnea, ankyloglossia and breastfeeding, frenotomy indications and informed consent, frenotomy procedure, ankyloglossia in older children, and maxillary labial frenulum.

Conclusion. This expert panel reached consensus on several statements that clarify the diagnosis, management, and treatment of ankyloglossia in children 0 to 18 years of age. Lack of consensus on other statements likely reflects knowledge gaps and lack of evidence regarding the diagnosis, management, and treatment of ankyloglossia. Expert panel consensus may provide helpful information for otolaryngologists treating patients with ankyloglossia.

Keywords

ankyloglossia, tongue-tie, lip tie, frenotomy, frenuloplasty, lingual frenulum, frenectomy, frenulotomy, frenuloplasty, maxillary labial frenulum, maxillary frenotomy, breastfeeding

Received November 25, 2019; accepted February 15, 2020.

Introduction

Medical practitioners have long been concerned that a restrictive lingual frenulum could adversely affect a child's health by interfering with the ability to breastfeed, speak, or perform mechanical/social skills, such as licking the lips or keeping the teeth clean. In 1679, a surgical textbook was published with woodcuts showing an infant's frenulum being cut with scissors.¹ Midwives in the 18th century reportedly kept 1 fingernail long so that they could lyse the frenulum following birth to facilitate breastfeeding.²

Over the past decade, there has been an exponential increase in the number of children diagnosed and treated with ankyloglossia in more affluent countries. A 2017 study by Walsh et al of pediatric inpatients in the United States

¹Otolaryngology–Head and Neck Surgery, Baylor College of Medicine/Texas Children's Hospital, Houston, Texas, USA

²Johns Hopkins University, Baltimore, Maryland, USA

³SUNY Downstate Medical Center, Brooklyn, New York, USA

⁴Virginia Mason Medical Center, Seattle, Washington, USA

⁵Cincinnati Children's Hospital Medical Center, Cincinnati, Ohio, USA

⁶Eastern Virginia Medical School, Norfolk, Virginia, USA

⁷Nemours Specialty Care, Wolfson Children's Hospital, St. Johns, Florida, USA

⁸Boston University and Boston Medical Center, Boston, Massachusetts, USA

⁹UCSF School of Medicine, San Francisco, California, USA

¹⁰University of Washington Seattle Children's Hospital, Seattle, Washington, USA

¹¹Children's Hospital of Pittsburgh, Pittsburgh, Pennsylvania, USA

¹²Pediatric Otolaryngology Associates, LLC, Jacksonville, Florida, USA

¹³American Academy of Otolaryngology–Head and Neck Surgery Foundation, Alexandria, Virginia, USA

Corresponding Author:

Anna H. Messner, MD, Otolaryngology–Head and Neck Surgery, Baylor College of Medicine/Texas Children's Hospital, Mark Wallace Tower, 6701 Fannin St, Suite 540, Houston, TX 77030, USA.

Email: messner@bcm.edu

demonstrated that between 2003 and 2012, there was a 4-fold increase in the number of newborns diagnosed with ankyloglossia and a 5-fold increase in the number of frenotomies.³ Similarly, a 2017 study in Canada found “run-away” rates of frenotomy for infants in some territories.⁴ In the Canterbury province of New Zealand, the frenotomy rate increased from a relative high of 7.5% to 11.3% in just 2 years (between 2013 and 2015).⁵

Despite growing attention to ankyloglossia in recent years, the benefit of and indications for intervention are unclear and controversial, given the paucity of randomized controlled trials.⁶ A Cochrane review of frenotomy in newborns concluded that it “reduced breastfeeding mothers’ nipple pain in the short term,” but the investigators did not find a consistent positive effect on infant breastfeeding.⁷ A systematic review evaluating frenotomy for reasons other than breastfeeding found that “data are currently insufficient for assessing the effects of frenotomy on nonbreastfeeding outcomes that may be associated with ankyloglossia.”⁸

Ideally, a clinical guideline would be developed to assist practitioners faced with infants and children with possible ankyloglossia; however, the quality and quantity of existing high-level evidence are insufficient for developing a multidisciplinary clinical practice guideline. Given this deficit, the American Academy of Otolaryngology—Head and Neck Surgery Foundation (AAO-HNSF) prioritized developing a clinical consensus statement (CCS) based on the views of expert panelists who actively treat patients with ankyloglossia and other oral ties. The objectives of the CCS are to identify areas of expert consensus—and nonconsensus—regarding the definitions of ankyloglossia, lip tie, and buccal tie; the indications for surgical intervention; perioperative management; and the expected outcomes.

Methods

This CCS was developed with an a priori protocol,⁹ used by the AAO-HNSF to successfully develop multiple other consensus statements, with the following steps: (1) define the subject of a CCS as evaluation of the diagnosis, management, and treatment of ankyloglossia; (2) recruit the expert panel; (3) vet potential conflicts of interest among proposed panel members; (4) perform a systematic literature review; (5) determine the scope and population of interest for the CCS; (6) develop topic questions and consensus for statements for each topic question; (7) develop and implement modified Delphi method surveys; (8) revise the CCSs in an iterative fashion based on survey results; and (9) aggregate the data for analysis and presentation. The pertinent details of these steps are briefly described.

Determination of Ankyloglossia as the Topic of a CCS, Panel Recruitment, and Vetting

Ankyloglossia was proposed for a CCS by the American Society of Pediatric Otolaryngology. After deliberation, the AAO-HNSF Guidelines Taskforce approved and prioritized the suggestion; consensus panel leadership was selected; and administrative support was allocated. Panel membership was

strategically developed to ensure appropriate representation of all relevant stakeholder groups and organizations within otolaryngology. The stakeholders were contacted regarding the consensus statement project and the requirements and desired qualifications for panel membership; each group then nominated its own representative content expert to participate.

The CCS development committee was made up of representatives from the American Society of Pediatric Otolaryngology; the Society of Ear, Nose, and Throat Advances in Children; the Triological Society; and appropriate committees within the AAO-HNSF, including the Board of Governors, the General and Sleep Clinical Advisory Committee, and the Pediatric Clinical Advisory Committee. The methodologists were nonvoting members of the development group.

All panel members are pediatric otolaryngologists in clinical practice who actively evaluate and treat children with ankyloglossia and other oral anomalies (including the performance of surgical procedures). All were required to agree in advance of appointment to participate in all verbal discussions (performed via teleconference) and votes. Once the panel was assembled, complete disclosure of potential conflicts of interest was reported and vetted within the group. Conflicts of interest were managed consistent with the Council of Medical Specialty Societies’ *Code for Interactions with Companies*,¹⁰ which requires that the chair and a majority of the participants do not have a direct conflict with the deliberations. The panel chair and assistant chair led the development of the clinical statements and the Delphi process with input from a senior consultant/methodologist from AAO-HNSF leadership and AAO-HNSF Guidelines Taskforce and with administrative support from an AAO-HNSF staff liaison.

Literature Review and Determination of the Scope of the Consensus Statement

Two systematic literature reviews were performed by an information specialist, using keywords identified by the development panel, to identify current evidence regarding the diagnosis, management, and treatment of ankyloglossia and oral ties.

The literature searches were conducted in December 2018 and March 2019 and restricted to year of publication from January 1, 2000, to December 31, 2018. Articles included all relevant publications in English from the following databases: PubMed, EMBASE, Cumulative Index to Nursing and Allied Health Literature, Cochrane Database of Systematic Reviews, Web of Science, Agency for Healthcare Research and Quality, ECRI National Guideline Clearinghouse, Canadian Medical Association Infobase, NHS Evidence ENT and Audiology, TRIP Database, Clinicaltrials.gov, Canadian Agency for Drugs and Technologies in Health, New Zealand Guidelines Group, Australian National Health and Medical Research Council, Guidelines International Network, and SCOPUS. The keyword strategy was as follows:

(lingual frenum[mesh] OR ankyloglossia[mesh] OR ankyloglossia*[tiab] OR “tongue tie” OR “Tongue ties” OR

tongue-tie OR tongue-ties OR Frenotom*[tiab] OR frenulotomy*[tiab] OR frenulectom*[tiab] OR “lingual frenum” OR “lingual frenums” OR fraenectom*[tiab] OR frenulae[tiab])

The *target audience* of the CCS was defined as otolaryngologists treating patients with ankyloglossia in any clinical setting, including the operating room, ambulatory surgery center, physician’s office, and outpatient clinics. The *target population* was defined as children aged 0 to 18 years, including breastfeeding infants. Once the target population and scope of practice were determined, the panel used the results of the literature reviews, combined with its expert opinion and stakeholder needs, to identify and prioritize topics and questions for which knowledge gaps or uncertainty existed, which could most benefit from potential consensus from an expert panel. These areas were then used as the basis for the formulation of the initial statements, which were then evaluated through the Delphi survey method.

Delphi Survey Method Process and Administration

A modified Delphi survey method was utilized to assess consensus for the proposed statements,⁹ with multiple anonymous surveys to minimize bias within the expert panel and facilitate consensus.¹¹

Web-based software (www.surveymonkey.com) was used to administer confidential surveys to panel members. A potential topic list of 37 questions was developed by the panel during the first call, and all panel members were invited to provide 1 draft statement for each of their top 5 ranked choices. The survey period was divided into 3 Delphi rounds. All answers were deidentified and remained confidential; however, names were collected to ensure proper follow-up, if needed.

Based on the outcomes of the top ranked topic list choices and resulting discussion, the panel chair and assistant chair developed the first Delphi survey, which consisted of 57 statements. Prior to dissemination to the panel, the Delphi surveys were reviewed by the methodologist for content and clarity. Questions in the survey were answered with a 9-point Likert scale (1 = strongly disagree, 3 = disagree, 5 = neutral, 7 = agree, 9 = strongly agree). The surveys were distributed, and responses were aggregated, distributed back to the panel, discussed via teleconference, and revised, if warranted. The purpose of the teleconference was to provide an opportunity to clarify any ambiguity, propose revisions, or drop any statements recommended by the panel.

The criteria for consensus were established a priori and are as follows⁹:

Consensus: statements achieving a mean score ≥ 7.00 and having no more than 1 outlier, defined as any rating ≥ 2 Likert points from the mean in either direction

Near consensus: statements achieving a mean score ≥ 6.50 and having no more than 2 outliers

No consensus: statements that did not meet the criteria of consensus or near consensus

Three iterations of the Delphi survey were performed. The panel extensively discussed (via teleconference) the results of each item after the first Delphi survey. Items that reached consensus were accepted, and items that did not meet consensus were discussed to determine if wording or specific language was pivotal in the item not reaching consensus. The second and third iterations of the survey were used to reassess items for which there was near consensus or for items for which there were suggestions for significant alterations in wording that could have affected survey results. All items reaching consensus were accepted, except for 4 statements that were removed due to redundancy. The factors leading to the remaining items not reaching consensus were not attributed to wording or other modifiable factors but rather a true lack of consensus.

The final version of the CCSs were grouped into specific topics: ankyloglossia (general); buccal tie, ankyloglossia, and sleep apnea; ankyloglossia and breastfeeding; frenotomy indications and informed consent; frenotomy procedure; ankyloglossia in older children; and maxillary labial frenulum (MLF). The items most likely to direct the practice of otolaryngologists were also grouped. The final manuscript was drafted with participation and final review from each panel member.

Results

The initial literature search yielded 202 articles, with 104 remaining after the titles and abstracts were screened for relevance. Additional exclusions at this stage included commentaries, letters to the editor, editorials, studies in animals, and research limited to adults. The remaining 104 articles were reviewed independently by the chair and assistant chair and classified per the Oxford Centre for Evidence-Based Medicine (CEBM) 2011 levels of evidence.¹² An additional 7 articles were included outside the literature searches on the basis of panel agreement of relevance and not being captured in the 2 literature searches. The CEBM evidence levels included 14 level 1 articles, 7 level 2 articles, 19 level 3 articles, 54 level 4 articles, and 17 level 5 articles.

A total of 89 clinical statements were developed for assessment throughout the 3 iterations of the Delphi survey. After removal of duplicative statements and combination of similar statements, 86 statements remained for assessment. All panelists completed all survey items. After 3 iterations of the Delphi survey, 41 statements (48%) met the standardized definition for consensus (**Tables 1-7**), and 45 (52%) did not (**Tables 8-12**). Statements most likely to direct the practice of otolaryngologists are also presented (**Table 13**). The clinical statements were organized into the specific subject areas.

Discussion

Ankyloglossia (General)

As there is increasing awareness, diagnosis, and treatment of ankyloglossia globally, there is a need for common definitions.^{3,4,6,13-16} With regard to defining ankyloglossia, this

Table 1. Statements That Reached Consensus: Ankyloglossia (General).

No.	Statement	Mean	Outliers
4c	Ankyloglossia is a condition of limited tongue mobility caused by a restrictive lingual frenulum.	8.00	0
6b	In recent years, some practitioners have described ankyloglossia as being anterior or posterior.	8.18	1
6c	Those practitioners who describe ankyloglossia as being anterior or posterior typically use the term anterior ankyloglossia to refer to a lingual frenulum that extends to the tip of the tongue or near the tip of the tongue that restricts tongue mobility.	7.45	1
2b	In some communities, infants and children are being over-diagnosed with ankyloglossia.	8.09	0
3b	In some communities, a significant number of children are having unnecessary surgery on the lingual frenulum.	7.82	0

Table 2. Statements That Reached Consensus: Buccal Tie/Ankyloglossia and Sleep Apnea.

No.	Statement	Mean	Outliers
36	Surgery to release a “buccal tie” should not be performed.	8.64	1
54	Ankyloglossia does not cause sleep apnea.	8.36	0

Table 3. Statements That Reached Consensus: Ankyloglossia and Breastfeeding.

No.	Statement	Mean	Outliers
10	Breastfeeding difficulties are common in the newborn period and evidence shows that anterior ankyloglossia is a potential contributor to infant feeding problems	7.82	1
12	Maternal pain and poor infant latch can be caused by ankyloglossia but these symptoms can also be present with other etiologies of breastfeeding difficulties	8.73	0
8	Ankyloglossia in an infant should be evaluated by a careful history (including lactation history) and physical examination, including inspection and palpation	8.85	0
19	The maternal and infant breastfeeding dyad should be recognized as a vulnerable patient population and care should be taken to ensure adequate support services, education and counselling, and shared decision making.	8.82	0
20	Infants should ideally be evaluated by a lactation consultant prior to lingual frenotomy	7.27	1

panel mirrors the disagreements and uncertainty of the medical community. The panel achieved clear consensus in describing ankyloglossia as a “condition of limited tongue mobility caused by a restrictive lingual frenulum” (**Table 1**). The panel also acknowledged that, in recent years, practitioners have been using the terms “anterior” and “posterior” ankyloglossia and that those practitioners who use the term “anterior” ankyloglossia are referring to a lingual frenulum that extends to the tip of the tongue or near the tip of the tongue and restricts tongue mobility (**Figure 1A**). But some panelists do not use this term and equate “ankyloglossia” with “anterior ankyloglossia.” When the definition of posterior ankyloglossia was considered, the panel was unable to achieve consensus.¹⁷⁻²² Some in the group use the term to mean a frenulum that inserts into the posterior portion of the tongue, whereas others think of it as a submucosal tethering of the tongue (**Figure 1B**). Still others feel that it does not exist as an anatomic entity and that the term “posterior ankyloglossia” should be abandoned.¹⁷⁻²⁴ **Figure 1** shows an example of anterior versus possible posterior ankyloglossia.

As a result of definition disagreement and the lack of validated grading tools, the group was unable to recommend a preferred ankyloglossia grading system. Some grading systems, such as the Coryllos classification, focus on the type of frenulum but do not address functionality or criteria for ankyloglossia. Other systems, such as the Hazelbacker Assessment Tool for Lingual Frenulum Function or Bristol Tongue Assessment Tool, attempt to include functionality and ankyloglossia scoring.^{22,24-28} The panel’s consensus regarding ankyloglossia as a “condition of limited tongue mobility caused by a restrictive lingual frenulum” emphasizes the importance of demonstrating tongue mobility restriction and isolating that restriction to the lingual frenulum. Therefore, a diagnosis of ankyloglossia without limited tongue mobility and/or without a restrictive lingual frenulum should be reconsidered.

The reported incidence of ankyloglossia ranges from 2.8% to 10.7%,^{29,30} with a noted increase in recent years due in part to a widening definition of ankyloglossia. Traditionally, the terms “ankyloglossia” and “tongue-tie” referred to a frenulum that extended close or to the tongue

Table 4. Statements That Reached Consensus: Frenotomy Indications and Informed Consent.

No.	Statement	Mean	Outliers
22	Before performing a frenotomy on an infant with breastfeeding difficulty, it is appropriate to evaluate the child for other potential head and neck sources of breastfeeding problems such as nasal obstruction, airway obstruction, laryngopharyngeal reflux, and craniofacial anomalies (eg cleft palate).	8.00	1
23b	Relative contraindications to infant frenotomy include, but are not limited to, retrognathia, micrognathia, neuromuscular disorder, hypotonia, and coagulopathy.	8.18	0
25	Rare complications of lingual frenotomy include hemorrhage, airway obstruction, injury to salivary structures, oral aversion, and scarring.	7.91	0
27	Informed consent for lingual frenotomy should include mention of the possibility of failure to experience improvement in breastfeeding.	8.82	0
37	Breastfeeding difficulty and maternal pain in the presence of ankyloglossia may resolve without surgical treatment.	8.18	0
28	Patients and caregivers of patients with ankyloglossia should be counselled about the non-surgical options of observation, lactation consultation, and/or speech-language pathology consultation.	8.55	0
43b	Potential benefits from lingual frenotomy in the infant with breastfeeding difficulties are relief of maternal symptoms (eg less pain) and maternal reported improvement in infant feeding	8.18	1
44	Frenotomy is not always effective in relieving maternal pain and breastfeeding difficulty.	7.91	1
38b	Maternal reported breastfeeding efficacy and nipple pain in the presence of ankyloglossia are more likely to improve with lingual frenotomy compared to no surgical treatment.	7.73	1
31/32b	Lingual frenotomy should ideally be performed as soon as possible after diagnosis of ankyloglossia in an infant with breastfeeding problems not improving with conservative management.	7.73	1
33c	It is not necessary to perform lingual frenotomy in an infant with little or no restriction in tongue mobility to prevent a future feeding disorder.	8.55	0
33d	It is not necessary to perform lingual frenotomy in an infant with little or no restriction in tongue mobility to prevent a future speech disorder.	7.91	1

Table 5. Statements That Reached Consensus: Frenotomy Procedure.

No.	Statement	Mean	Outliers
24	Lingual frenotomy is generally a safe and well-tolerated procedure	8.00	0
30b	Topical anesthetic agents are not recommended prior to infant frenotomy.	7.82	1
30c	Injected anesthetic agents are not recommended prior to infant frenotomy.	7.82	1
30d	Oral sucrose has been shown to decrease pain response in infants undergoing procedures and can be given to an infant prior to undergoing frenotomy.	7.73	1
39	There is insufficient evidence to support claims that one technique of frenotomy, such as laser, is superior to other techniques.	8.09	1
42b	After frenotomy is performed for ankyloglossia there is no evidence to support a standard post-procedure care regimen (eg stretching, massaging, manual elevation of the tongue by the parents).	7.36	1

tip, limiting movement of the tongue. Over the last decade—with the more expansive description of tongue-tie including anterior and posterior tongue-tie and with a broader range of attributed symptoms, as well as a lack of standardized diagnostic criteria—many more children are being diagnosed with ankyloglossia.^{3-5,14,31} The panel reached consensus that, in some communities, infants and children are being overdiagnosed with ankyloglossia and having unnecessary surgery (**Table 1**). Additional potential

factors that have led to more children being diagnosed with ankyloglossia include (1) an increased focus on the benefits of breastfeeding; (2) an increased awareness that ankyloglossia can negatively affect breastfeeding; (3) an increase in the number of lactation consultants who identify infants with possible ankyloglossia; (4) an increase in social media and websites related to tongue-tie, and (5) an increase in the number of medical practitioners, particularly dentists, who treat ankyloglossia.³⁻⁵

Table 6. Statements That Reached Consensus: Ankyloglossia in Older Children.

No.	Statement	Mean	Outliers
13b	Ankyloglossia does not typically affect speech.	7.82	1
34	A consultation with a speech pathologist is encouraged before frenotomy/frenuloplasty in an older child who is undergoing the procedure for speech concerns.	7.73	0
48b	Ankyloglossia may cause social/mechanical issues in older children (difficulty licking, difficulty keeping teeth clean, lower central incisor diastema, sense of social embarrassment)	7.55	1
49b	Some older children with social/mechanical issues related to ankyloglossia will experience improved quality of life after frenotomy/frenuloplasty.	7.91	1
14	There is no maximum age for a patient undergoing frenotomy/frenuloplasty.	7.73	1
35	There is not a preferred surgical procedure for correction of ankyloglossia in the older child.	7.55	1

Table 7. Statements That Reached Consensus: Maxillary Labial Frenulum.

No.	Statement	Mean	Outliers
15	Presence of an upper lip frenulum is normal in an infant.	8.45	0
17b	Upper lip tie is an inconsistently defined condition.	7.91	0
17c	Upper lip tie has an unclear relationship to breastfeeding difficulties.	7.27	1
17d	In some communities upper lip tie is being overdiagnosed.	8.18	1
56c	Upper lip frenotomy in infants or children with primary dentition will not prevent the occurrence of an upper interincisor diastema.	7.82	0

Table 8. Key Statements That Did Not Reach Consensus: Ankyloglossia (General).

No.	Statement	Mean	Outliers
7	The Coryllos grading scale and images are preferred for diagnosing ankyloglossia and for distinguishing anterior vs posterior attachment	4.82	8
6d	Those practitioners who describe ankyloglossia as being anterior or posterior typically use the term posterior ankyloglossia to describe a lingual frenulum that attaches to the posterior aspect of the tongue and decreases tongue mobility.	6.18	6
6	Posterior ankyloglossia refers to a frenulum that attaches to the posterior aspect of the tongue and restricts tongue mobility	4.45	6

Table 9. Key Statements That Did Not Reach Consensus: Ankyloglossia and Breastfeeding.

No.	Statement	Mean	Outliers
11	Breastfeeding difficulties are common in the newborn period and evidence shows that posterior ankyloglossia is a potential contributor to infant feeding problems	4.36	4
21	Evaluation of an infant prior to lingual frenotomy by a lactation consultant is unnecessary.	3.73	3

Buccal Tie

The term “buccal tie” has been used to describe a perceived tightness in the maxillary and/or mandibular buccal frenula. The buccal frena are small connective tissue folds between the buccal mucosa and the maxillary or mandibular

gingiva typically located between the canines and premolars. They correspond to the lateral border of the lower portion of the incisivus labii superioris fibers of the orbicularis oris muscle or the anterior border of the buccinator muscle.³² As such, the buccal frenulum augments the role

Table 10. Key Statements That Did Not Reach Consensus: Infant Frenotomy.^a

No.	Statement	Mean	Outliers
29c	The office setting is the preferred location for frenotomy whenever possible (particularly in infants) so that general anesthesia can be avoided.	7.00	8
47	After performing lingual frenotomy for breastfeeding difficulties, it is best to observe the child actively breastfeeding and to question the mother regarding any changes noted.	5.00	7
29	Lingual frenotomy can be performed at any age in the office setting or the operating room based on clinician experience and patient preference. The office setting is preferred whenever possible (particularly in infants) so that general anesthesia can be avoided.	6.36	6
29b	Lingual frenotomy can be performed at any age in the office setting or the operating room based on clinician experience and patient preference.	6.64	5
26	Informed consent for lingual frenotomy should include a discussion of rare complications	6.55	5
45	Compared to anterior ankyloglossia, frenotomy for posterior ankyloglossia is not as effective in resolving breastfeeding difficulties.	6.45	4
40b	Lingual frenotomy in an infant with severe tongue restriction, even without breastfeeding difficulties, may prevent the need for general anesthesia if the frenotomy is deferred to a later age.	5.91	3
42	After frenotomy is performed for posterior ankyloglossia there is no evidence to support a standard post-procedure care regimen (eg stretching, massaging, manual elevation of the tongue by the parents).	7.27	2
46	After frenotomy, follow up should be available to assess for complications or lack of improvement.	7.18	2
32	The ideal age for frenotomy in infants with ankyloglossia and breastfeeding difficulties is less than 3 months of age.	7.09	2

^aItems in bold text reached “near consensus”; all other items reached “no consensus.”

Table 11. Key Statements That Did Not Reach Consensus: Ankyloglossia in Older Children.

No.	Statement	Mean	Outliers
50	There is no evidence that untreated posterior ankyloglossia results in symptoms in the older child.	6.82	5

Table 12. Key Statements That Did Not Reach Consensus: Maxillary Labial Frenulum.

No.	Statement	Mean	Outliers
53	When an infant with breastfeeding difficulties has both tongue tie and upper lip tie, the tongue tie should be released first, the impact on breastfeeding assessed, and the lip tie released only if the outcome is not optimal.	5.18	5
55	There is no evidence to suggest that routine release of the upper maxillary frenulum positively affects breastfeeding.	6.91	4
16	Presence of an upper lip frenulum that restricts ability of the infant to evert the lip during breast or bottle feeding is normal.	3.91	4
51b	Despite little evidence to suggest that release of a restrictive upper maxillary frenulum positively affects breastfeeding, there may be potential benefits in the appropriately selected patient.	6.27	3
18	A symptomatic upper lip tie may be diagnosed when the lip is restricted from flaring around the breast in a manner that facilitates breastfeeding.	5.45	2
52	When an infant with breastfeeding difficulties has both tongue tie and upper lip tie, they should be release concurrently.	2.64	1

of the buccinator in keeping the bolus between the teeth and in a medial position during the oral preparatory phase of swallowing. The importance of this function is underscored by evidence that manual cheek support enhances suction

during breastfeeding.³³ Therefore, it is illogical that division or resection of the buccal frenulum would be useful in facilitating breastfeeding in infants. Furthermore, there are no existing criteria used to determine whether the buccal

Table 13. Ankyloglossia and Oral Tie Action Statements for Clinicians.^a

No.	Statement	Mean	Outliers
10	Breastfeeding difficulties are common in the newborn period and evidence shows that anterior ankyloglossia is a potential contributor to infant feeding problems	7.82	1
12	Maternal pain and poor infant latch can be caused by ankyloglossia but these symptoms can also be present with other etiologies of breastfeeding difficulties	8.73	0
8	Ankyloglossia in an infant should be evaluated by a careful history (including lactation history) and physical examination, including inspection and palpation	8.85	0
22	Before performing a frenotomy on an infant with breastfeeding difficulty, it is appropriate to evaluate the child for other potential head and neck sources of breastfeeding problems such as nasal obstruction, airway obstruction, laryngopharyngeal reflux, and craniofacial anomalies (e.g. cleft palate).	8.00	1
23b	Relative contraindications to infant frenotomy include, but are not limited to, retrognathia, micrognathia, neuromuscular disorder, hypotonia, and coagulopathy.	8.18	0
27	Informed consent for lingual frenotomy should include mention of the possibility of failure to experience improvement in breastfeeding.	8.82	0
30b	Topical anesthetic agents are not recommended prior to infant frenotomy.	7.82	1
30c	Injected anesthetic agents are not recommended prior to infant frenotomy.	7.82	1
30d	Oral sucrose has been shown to decrease pain response in infants undergoing procedures and can be given to an infant prior to undergoing frenotomy.	7.73	1
13b	Ankyloglossia does not typically affect speech.	7.82	1
48b	Ankyloglossia may cause social/mechanical issues in older children (difficulty licking, difficulty keeping teeth clean, lower central incisor diastema, sense of social embarrassment).	7.55	1
15	Presence of an upper lip frenulum is normal in an infant.	8.45	0
17c	Upper lip tie has an unclear relationship to breastfeeding difficulties.	7.27	1
56c	Upper lip frenotomy in infants or children with primary dentition will not prevent the occurrence of an upper interincisor diastema.	7.82	0
36	Surgery to release a “buccal tie” should not be performed.	8.64	1
54	Ankyloglossia does not cause sleep apnea.	8.36	0

^aThis table is a composition of important action items regarding ankyloglossia for clinicians to consider.

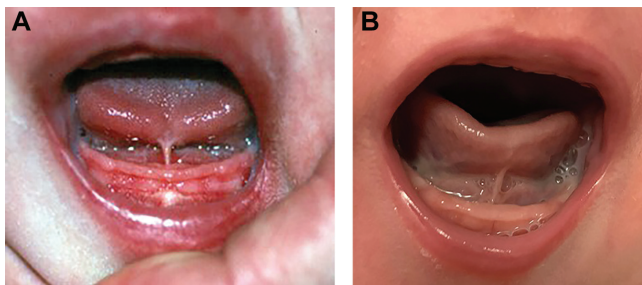


Figure 1. (A) An example of “anterior” ankyloglossia with the lingual frenulum attaching at the tongue tip, limiting tongue mobility. (B) Posterior attachment of lingual frenulum. Consensus was not reached regarding the definition of “posterior” ankyloglossia. Some in the consensus group would describe this figure as an example of posterior ankyloglossia if there are objective findings of restricted tongue mobility caused by the lingual frenulum.

frenulum is restrictive. The panel reached a consensus recommendation against release of buccal frenula (**Table 2**).

Ankyloglossia and Sleep Apnea

The notion that a short lingual frenulum may result in orofacial changes associated with obstructive sleep apnea (OSA)

is being advocated by some in health care, particularly dentists. The presumption is that a short frenulum tethers the tongue to the floor of mouth, resulting in a narrow palatal arch and abnormal maxillary growth. While a narrow palatal arch has been shown to contribute to OSA,^{34,35} only a single small retrospective study has been cited as evidence of a direct association between ankyloglossia and OSA.³⁶ It should also be noted that anterior tethering of the tongue serves, to some degree, to prevent posterior collapse of the tongue and that if the frenulum is released, it could lead to worsening OSA.^{37,38} The panel reached consensus that there is no evidence that ankyloglossia causes sleep apnea (**Table 2**).

Ankyloglossia and Breastfeeding

There was strong consensus among members of the panel that the maternal and infant breastfeeding dyad should be recognized as a vulnerable patient population and that care should be taken to ensure adequate support services, education and counseling, and shared decision making (**Table 3**). This statement has implications in treatment choices, timing, obtaining consent, and outcome expectations, particularly in the current setting of poorly defined indications and diagnostic criteria.

Clarifying indications and diagnostic criteria is essential for limiting overtreatment while ensuring that infants who would benefit from frenotomy are treated in a timely manner. In addition, the long-term effects on breastfeeding rates for infants who undergo frenotomy are not clear. In the province of Canterbury, New Zealand, the introduction of a standardized clinical pathway for infants with ankyloglossia aimed at supporting breastfeeding and avoiding unnecessary surgery resulted in a marked decrease in the frenotomy rate (11.3% in 2015 to 3.5% in 2017), without negatively affecting the rate of breastfeeding.⁵ More recently, a study conducted in Boston demonstrated similar dramatic reductions in frenotomy rates.³⁹

Ankyloglossia is one of several factors that can contribute to breastfeeding problems. The panel reached consensus that pain and poor latch can be caused by ankyloglossia, but these symptoms can be present with other etiologies.^{40,41} As tongue-tie can be identified on a simple oral examination, it is often targeted by providers and/or parents as the primary causative factor for breastfeeding difficulties. Thus, the panel also found consensus that before a frenotomy is performed on an infant with breastfeeding difficulty, it is appropriate to evaluate the child for other potential head and neck sources of breastfeeding problems (**Table 3**). It is also clear that not all infants with ankyloglossia have breastfeeding problems.⁴² Ankyloglossia does not by itself indicate that surgical release must be performed, because many infants can still adequately feed without any surgical intervention.^{39,43} The evaluating provider should fully assess the clinical situation to include the degree of maternal/infant breastfeeding impairment and the physical examination and then devise a management plan that incorporates all of this information as well as the desires and preferences of the family (shared decision-making). As shown by the control groups in the available randomized clinical trials, many infants with varying degrees of ankyloglossia feed well despite no surgical intervention.⁴⁴⁻⁴⁶

For those infants with breastfeeding challenges, the most commonly associated symptoms of ankyloglossia in the newborn include nipple pain with nursing, irritation of the nipple skin, and shallow/poor latch.^{29,30,47,48} The evaluation of an infant referred for ankyloglossia should not be limited to a cursory assessment of only the lingual frenulum. It is important to obtain the lactation history, including previous breastfeeding experience (experienced mothers will often state that the latch feels different with the tongue-tied baby), the frequency and length of breastfeeding sessions, whether formula supplementation or pumping is being used, and whether lactation support has been utilized.²¹ Maternal factors that should be considered include common discomfort during the first few weeks of breastfeeding, maternal nipple anatomy, poor positioning/support at breast, maternal milk supply, and breast infection.⁴¹ Infant factors that should be considered include prematurity, abnormal palatal, mandibular or maxillary development, neurologic disorders, cardiovascular disorders, and upper airway obstruction leading to difficulty feeding. The physical examination should

include a close inspection of the tongue, mandible, maxilla, and palate, as well as assessment for signs of airway obstruction. Providers should also palpate the frenulum. While otolaryngologists have expertise in the anatomy and function of the head and neck, the majority of otolaryngologists have a cursory knowledge of breastfeeding methods and problems. Given that 70% to 90% of mother-infant dyads who are experiencing difficulty with breastfeeding have been found to have suboptimal positioning at the breast,^{40,41} excellent lactation services are essential for successful breastfeeding.

Lactation consultants may not always be able to diagnose ankyloglossia, but they should be able to (1) identify those infants who have not had breastfeeding success from normal interventions and may be affected by ankyloglossia or another medical condition and (2) refer the parents to an appropriate provider. All providers should be adept at assessing the individual needs and preferences of the mother-infant dyad and tailor interventions such that a shared plan is developed. After lingual frenotomy, the lactation consultant can support the dyad in ensuring a good latch has been established postprocedure.

Frenotomy Indications and Informed Consent

The panel reached consensus that before a frenotomy is performed on an infant with breastfeeding difficulty, it is appropriate to evaluate the child for other potential head and neck sources of breastfeeding problems^{23,43,49-51} (**Table 4**). Even in the context of ankyloglossia, the following situations can certainly contribute to neonatal difficulty at breastfeeding: nasal obstruction (eg, choanal atresia, piriform aperture stenosis), airway obstruction (eg, laryngomalacia, bilateral vocal fold paralysis), laryngopharyngeal reflux, and craniofacial abnormalities (eg, retrognathia, cleft palate). Failure to diagnose and treat these other disorders can cause increased patient morbidity and worse outcomes after lingual frenotomy.

The panel agreed that relative contraindications to infant frenotomy include, but are not limited to, retrognathia, micrognathia, neuromuscular disorder, hypotonia, and coagulopathy (**Table 4**). In patients with retrognathia, micrognathia, neuromuscular disorders, and hypotonia, performing a lingual frenotomy can worsen glossoptosis and lead to airway obstruction and concomitant dysphagia.^{37,38} Furthermore, in patients with neuromuscular disorders and hypotonia, the feeding difficulty may be multifactorial and related to these underlying issues, increasing the chance that the lingual frenotomy will not be successful and improve feeding.

If an infant has been diagnosed with ankyloglossia and there are breastfeeding problems—particularly maternal pain associated with the latch, which is not improving with conservative management (eg, positioning, nipple shields)—then a lingual frenotomy should be performed as soon as possible to decrease the likelihood that the mother will abandon breastfeeding.⁵² Once a mother has stopped breastfeeding, she will rarely restart, even if she has maintained her milk supply with pumping. The consensus group could

not agree on a specific patient age where infant frenotomy would be most helpful but generally agreed with published studies advocating for early frenotomy, including infants who are <1 month of age⁵²⁻⁵⁴ (**Table 10**).

The panel reached consensus on the statement that rare complications of lingual frenotomy include hemorrhage, airway obstruction, injury to salivary structures, oral aversion, and scarring (**Table 4**). Although they are rare, all of these complications have been reported in the literature, and many have been seen by the panelists.^{37,43,55-58}

The panel agreed that informed consent for lingual frenotomy should include mention of the possibility of failure to experience improvement in breastfeeding (**Table 4**). While much evidence in the literature supports the idea that lingual frenotomy can lead to improvement in breastfeeding,^{43,44,46,50,51,54,59-72} it is also important to recognize that not all infant-mother dyads experience breastfeeding improvement after the procedure.^{5,45,51,62}

The panel also reached consensus that patients and caregivers of patients with ankyloglossia should be counseled about nonsurgical options, including observation, lactation consultation, and/or speech-language pathology consultation (**Table 4**). It is important for caregivers to understand that there are treatment options and not all patients with ankyloglossia must undergo a lingual frenotomy. Breastfeeding difficulty can often improve with time or nonsurgical intervention by a lactation consultant or speech pathologist who specializes in breastfeeding issues.^{49,73}

The panel members all noted a recent significant clinical increase in referrals and parent requests for lingual frenotomy to prevent future feeding or speech disorders. Several studies support the panel's consensus that in infants with little or no tongue mobility restriction, frenotomy does not prevent future feeding or speech disorders.^{8,74-76}

Frenotomy Procedure

The panel reached strong consensus that lingual frenotomy is generally a safe and well-tolerated procedure (**Table 5**). This statement is well supported by the literature.^{7,19,77-79}

The panel agreed that there is insufficient evidence to support a specific technique (**Table 5**). The panel was aware that some providers are routinely using lasers as their tool of choice for frenotomy, but the panel felt that there was insufficient and conflicting evidence to support its use as being superior to other techniques.⁸⁰⁻⁸² This is critical in that different techniques may have cost implications for the patients. Additionally, terms such as “frenotomy,” “frenuloplasty,” and “frenectomy” have often been inappropriately used interchangeably. Frenotomy, or frenulotomy, is the usual procedure performed in infants: a simple incision of the lingual frenulum. The term “frenuloplasty” refers to an incision of the lingual frenulum with a rearrangement of the tissue (eg, horizontal to vertical, z-plasty). “Frenectomy” is the term used to describe removal of the lingual frenulum. This term has also been used with regard to the upper frenulum, where tissue is removed from the midline of the maxilla. They are distinct techniques that also have billing code

implications. The studies available for specific techniques were of low quality with high risk of bias.

The panel reached consensus that there is no evidence to support a standard postprocedure care regimen, including massage or stretching (**Table 5**). There are few data regarding ankyloglossia recurrence, the frequency of postprocedure oral aversion, and outcomes for frenotomy as a whole, so the panel was unable to support a statement that a postoperative regimen was beneficial.

Several factors influenced the panel in not reaching consensus on the utility of frenotomy for posterior ankyloglossia (**Table 10**). The panel was unable to reach consensus on a definition of posterior ankyloglossia, highlighting the controversy in the diagnostic criteria and its existence as a clinical entity (**Table 1**). Additionally, there is little evidence to demonstrate the efficacy of frenotomy in these patients, as the few studies available have a high risk of bias.^{19,23,49,50}

The panel did not support a preferred location in which to perform a frenotomy (clinic or operating room depending on age or patient/provider preference; **Table 10**). Many studies have found in-office frenotomy without general anesthesia to be a safe and effective treatment for infants with ankyloglossia.^{19,29,44-46,59,61,78,79} While it was generally acknowledged that older children would likely need general anesthesia, the consensus group could not agree on the exact circumstances that would lead to a recommendation for the procedures to be performed in the operating room as opposed to the clinic. In general, it is best to avoid general anesthesia in an infant if possible.⁷⁹

The panel reached consensus that topical anesthetic agents are not recommended prior to infant frenotomy (**Table 5**). Two small randomized studies found no advantage to the application of topical anesthetics.^{83,84} One safety concern is that topical benzocaine increases the risk of methemoglobinemia. In 2018, the Food and Drug Administration issued a warning that oral drug products containing benzocaine should not be used to treat infants and children <2 years old.⁸⁵ Injecting local anesthetic agents is not recommended prior to infant lingual frenotomy when performed in the office.

The panel reached consensus that oral sucrose has been shown to decrease pain response in infants undergoing procedures and can be given to an infant prior to undergoing frenotomy (**Table 5**). Sucrose is used commonly for other painful procedures during infancy, but its efficacy is debated, with some studies showing equal effectiveness with massage or breast milk.⁸⁶ Sucrose is unlikely to work in children >1 year of age,⁸⁷ and a minimally effective dose is not known.⁸⁸ Similarly, optimal timing before procedure is not known,⁸⁹ though 1 study suggests 2 minutes.⁹⁰

Ankyloglossia in Older Children

Much of the published literature regarding ankyloglossia has focused on infants; there is a paucity of literature regarding the indications and outcomes for frenuloplasty in older children and adolescents.⁸ While breastfeeding difficulty is often the primary concern in infants with

ankyloglossia, older children with ankyloglossia may present with concerns regarding speech, dentition, mechanical limitations, and social implications.

The consensus group concluded that ankyloglossia does not typically affect speech⁹¹ (**Table 6**). Even sounds that require the greatest amount of tongue elevation, /l/ and /r/, and protrusion, /th/, can usually be produced in the presence of significant tongue tip restriction. A few studies suggested an association between ankyloglossia and articulation difficulties, but they were of low quality.^{76,92,93} Studies on the impact of frenuloplasty on speech problems have also yielded conflicting results.^{74,76,92-95} Overall, studies evaluating speech outcomes in patients with ankyloglossia have suffered from the lack of control groups, randomization, and blinding; small sample sizes; and the use of nonvalidated subjective assessments. Another major limitation in many of the studies involves failure to adequately describe and standardize the utilization of speech therapy in subjects.^{8,96,97} As the true incidence of speech difficulties is unknown and there is no method to predict which children with ankyloglossia will require treatment, the consensus group agreed that consultation with a speech pathologist is encouraged prior to frenotomy/frenuloplasty for speech concerns.

The panel agreed that ankyloglossia may cause social/mechanical issues in older children (difficulty licking, difficulty keeping teeth clean, lower central incisor diastema, sense of social embarrassment; **Table 6**). There have been a few smaller studies but no randomized trials in children to determine whether frenuloplasty leads to definitive improvement in these types of mechanical and social issues.^{93,95,98} On the basis of our experience and the available literature, the panel concluded that some older children will have improved quality of life after frenotomy/frenuloplasty. There is no maximum age by which this procedure should be performed.

Data supporting the superiority of a specific frenuloplasty technique are lacking. As such, the panel agreed that there is not a preferred procedure for the correction of ankyloglossia in an older child (**Table 6**). There have been no randomized studies to compare outcomes between cold techniques and laser for frenuloplasty.⁹⁹ A small randomized study⁹² compared outcomes for 4-flap z-frenuloplasty and traditional horizontal-to-vertical frenuloplasty in children with ankyloglossia. While both procedures resulted in improvements in articulation and fluency, the 4-flap z-frenuloplasty group had improved articulation and superior tongue protrusion scores.

Maxillary Labial Frenulum

The MLF attaches the central portion of the upper lip to the maxillary alveolus between the central maxillary incisors. It consists of squamous epithelium; loose connective tissue; dense, irregular, collagenous connective tissue; and, in some cases, muscle fibers from the incisivus labii superioris portion of the orbicularis oris muscle.^{32,100,101} The MLF serves to provide stability for the upper lip.

Many cross-sectional studies demonstrated that the MLF is almost universally present as a normal, albeit variable,

structure.¹⁰² It is this variability that has led some clinicians to postulate that certain MLF presentations may be associated with either feeding difficulties in the newborn or later development of diastema. Unfortunately, investigators have yet to determine which, if any, classification schemes and presentations correlate with clinical symptoms,¹⁰³ and those in common use appear to demonstrate poor intra- and inter-rater reliability.¹⁰⁴

Regarding feeding issues, while several studies purport to establish the effectiveness of the MLF release for infant feeding difficulties,^{23,50,105} the studies are hampered by unclear definitions of lip tie, the absence of control groups, small patient cohorts, the presence of confounding variables, and short surgical follow-up. A recent systematic review identified no randomized controlled trials on the subject and concluded that the level of evidence for routine MLF release in infants with breastfeeding difficulties was poor.¹⁰³ The Australian Collaboration for Infant Oral Research has challenged the notion that “tie” of the lip even exists and suggested that the term be retired.¹⁰⁰ While several members of our panel concluded that there “is little evidence” to support MLF release when lip tie is suspected, others felt that the available studies and their personal experience suggest that some babies with poor lip eversion during breastfeeding may benefit from the procedure. The panel agreed that, in some communities, lip tie is being overdiagnosed (**Table 7**).

The literature is replete with studies of the association between MLF presentation and interincisor diastema.¹⁰⁶ Despite this fact, no definitive relationship between the two has been established.¹⁰⁶ In addition, studies suggest that despite short-term improvement in diastema obtained through MLF release, controls improve equally with age, presumably due to eruption of the canine teeth.^{102,106} Additionally, some authors have postulated that scarring resulting from MLF release in childhood may actually make diastema more likely in the permanent dentition.¹⁰⁰ The panel, like the Australian Collaboration for Infant Oral Research, therefore reached consensus that MLF release is not indicated for prevention of diastema in the permanent dentition (**Table 7**).

Strengths and Limitations

The strength of this study is the methodology of the consensus statement process. It is rigorous and follows an explicit, tested protocol to minimize conflicts of interest, minimize bias, and ensure consistency. Limitations of the study include the relatively small group of experts, all of whom are practicing pediatric otolaryngologists, and the lack of input from other professionals who evaluate children with ankyloglossia, including lactation consultants, pediatricians, and speech-language practitioners. In addition, there is a lack of CEBM level 1 studies to inform the panelists' opinions, and the majority of studies available have high levels of bias. Additional high-quality studies regarding ankyloglossia and other oral tie diagnosis and treatment are needed to further inform the practice of otolaryngologists and relevant medical specialists in the future.

Conclusions

This CCS was developed by pediatric otolaryngologists with the intention to promote appropriate, evidence-based care of the infant and child with possible ankyloglossia and/or upper lip tie. A series of clinical statements were developed by an expert panel using an objective survey method. While members of the consensus group all evaluate and treat children with ankyloglossia, the group found some marked differences in opinion regarding controversial topics, such as the definition (and even the existence) of posterior ankyloglossia and lip tie. While the group was able to come to consensus that frenotomy in infants with ankyloglossia can lead to an improvement in breastfeeding, not all infants with ankyloglossia need to have a frenotomy, and there are other more common causes of breastfeeding difficulties. A frenulum procedure is also an option in older children with speech articulation and/or other mechanical social issues, but the evidence is limited and of relatively poor quality. Similarly, the level of evidence surrounding intervention for the maxillary frenulum and possible upper lip tie is poor. Further study is needed to refine patient selection and outcome assessments in these areas. The application of these statements is expected to result in an improved understanding of the controversies surrounding ankyloglossia in children and lead to more family-centered care.

Acknowledgments

We gratefully acknowledge the support of Sarah Towner Wright, MLS, for conducting the literature searches.

The following organizations have endorsed this clinical consensus statement: American Society of Pediatric Otolaryngology (ASPO), Society of Ear, Nose, and Throat Advances in Children (SENTAC), and Triological Society.

Author Contributions

Anna H. Messner, writer, chair; **Jonathan Walsh**, writer, assistant chair; **Richard M. Rosenfeld**, writer, methodologist; **Seth R. Schwartz**, writer, methodologist; **Stacey L. Ishman**, writer, methodologist; **Cristina Baldassari**, writer, panel member; **Scott E. Brietzke**, writer, panel member; **David H. Darrow**, writer, panel member; **Nira Goldstein**, writer, panel member; **Jessica Levi**, writer, panel member; **Anna K. Meyer**, writer, panel member; **Sanjay Parikh**, writer, panel member; **Jeffrey P. Simons**, writer, panel member; **Daniel L. Wohl**, writer, panel member; **Erin Lambie**, writer, AAO-HNSF staff liaison; **Lisa Satterfield**, writer, AAO-HNSF staff liaison.

Disclosures

Competing Interests: Stacey L. Ishman, Inspire Medical—consultant; Anna K. Meyer, coauthor of the American Academy of Pediatrics clinical report; Daniel L. Wohl, Potential future intellectual property rights on prototype tongue elevator (provisionally filed for patent pending status September 20, 2018); Erin Lambie, salaried employee of AAO-HNSF; Lisa Satterfield, salaried employee of AAO-HNSF.

Sponsorships: American Academy of Otolaryngology—Head and Neck Surgery Foundation.

Funding source: None.

References

1. Scultetus J. *Wund-Artzneyisches Zeug-Hauss*. 1679.
2. Horton CE, Crawford HH, Adamson JE, Ashbell TS. Tongue-tie. *Cleft Palate J*. 1969;6:8-23.
3. Walsh J, Links A, Boss E, Tunkel D. Ankyloglossia and lingual frenotomy: national trends in inpatient diagnosis and management in the United States, 1997-2012. *Otolaryngol Head Neck Surg*. 2017;156(4):735-740.
4. Lisonek M, Liu S, Dzakpasu S, Moore AM, Joseph KS. Changes in the incidence and surgical treatment of ankyloglossia in Canada. *Paediatr Child Health*. 2017;22(7):382-386.
5. Dixon B, Gray J, Elliot N, Shand B, Lynn A. A multifaceted programme to reduce the rate of tongue-tie release surgery in newborn infants: observational study. *Int J Pediatr Otorhinolaryngol*. 2018;113:156-163.
6. Bin-Nun A, Kasirer YM, Mimouni FB. A dramatic increase in tongue tie-related articles: a 67 years systematic review. *Breastfeed Med*. 2017;12(7):410-414.
7. O'Shea JE, Foster JP, O'Donnell CPF, et al. Frenotomy for tongue-tie in newborn infants. *Cochrane Database of Syst Rev*. 2017;(3):CD011065.
8. Chinnadurai S, Francis DO, Epstein RA, Morad A, Kohanim S, McPheeters M. Treatment of ankyloglossia for reasons other than breastfeeding: a systematic review. *Pediatrics*. 2015;135(6):E1467-E1474.
9. Rosenfeld RM, Nnacheta LC, Corrigan MD. Clinical consensus statement development manual. *Otolaryngol Head Neck Surg*. 2015;153(2):S1-S14.
10. Council of Medical Specialty Societies. *Code of Interactions With Companies*. Chicago, IL: Council of Medical Specialty Societies; 2015.
11. Dalkey N, Helmer O. An experimental application of the Delphi method to the use of experts. *Manage Sci*. 1963;9(3):458-467.
12. Oxford Centre for Evidence-Based Medicine Work Group. The Oxford levels of evidence 2. <https://www.cebm.net/index.aspx?o=5653>. Published 2011. Accessed November 7, 2018.
13. Gonzalez Jimenez D, Costa Romero M, Riano Galan I, Gonzalez Martinez MT, Rodriguez Pando MC, Lobete Prieto C. Prevalence of ankyloglossia in newborns in Asturias (Spain). *An Pediatr (Barc)*. 2014;81(2):115-119.
14. Jin RLR, Sutcliffe A, Vento M, et al. What does the world think of ankyloglossia? *Acta Paediatr*. 2018;107(10):1733-1738.
15. Joseph KS, Kinniburgh B, Metcalfe A, Razaz N, Sabr Y, Lisonkova S. Temporal trends in ankyloglossia and frenotomy in British Columbia, Canada, 2004-2013: a population-based study. *CMAJ Open*. 2016;4(1):E33-E40.
16. Kapoor V, Douglas PS, Hill PS, Walsh LJ, Tennant M. Frenotomy for tongue-tie in Australian children, 2006-2016: an increasing problem. *Med J Aust*. 2018;208(2):88-89.

17. Hong P, Lago D, Seargeant J, Pellman L, Magit AE, Pransky SM. Defining ankyloglossia: a case series of anterior and posterior tongue ties. *Int J Pediatr Otorhinolaryngol.* 2010;74(9):1003-1006.
18. Mills N, Keough N, Geddes DT, Pransky SM, Mirjalili SA. Defining the anatomy of the neonatal lingual frenulum. *Clin Anat.* 2019;32(6):824-835.
19. O'Callahan C, Macary S, Clemente S. The effects of office-based frenotomy for anterior and posterior ankyloglossia on breastfeeding. *Int J Pediatr Otorhinolaryngol.* 2013;77(5):827-832.
20. Ruffoli R, Giambelluca M, Scavuzzo MC, et al. Ankyloglossia: a morphofunctional investigation in children. *Oral Dis.* 2005;11(3):170-174.
21. Walker RD, Messing S, Rosen-Carole C, McKenna Benoit M. Defining tip-frenulum length for ankyloglossia and its impact on breastfeeding: a prospective cohort study. *Breastfeed Med.* 2018;13(3):204-210.
22. Walsh J, Tunkel D. Diagnosis and treatment of ankyloglossia in newborns and infants a review. *JAMA Otolaryngol Head Neck Surg.* 2017;143(10):1032-1039.
23. Pransky SM, Lago D, Hong P. Breastfeeding difficulties and oral cavity anomalies: the influence of posterior ankyloglossia and upper-lip ties. *Int J Pediatr Otorhinolaryngol.* 2015;79(10):1714-1717.
24. Yoon A, Zaghi S, Weitzman R, et al. Toward a functional definition of ankyloglossia: validating current grading scales for lingual frenulum length and tongue mobility in 1052 subjects. *Sleep Breath.* 2017;21(3):767-775.
25. Amir LH, James JP, Donath SM. Reliability of the Hazelbaker Assessment Tool for lingual frenulum function. *Int Breastfeed J.* 2006;1(1):3.
26. Brandao CD, de Marsillac MDS, Barja-Fidalgo F, Oliveira BH. Is the Neonatal Tongue Screening Test a valid and reliable tool for detecting ankyloglossia in newborns? *Int J Pediatr Dent.* 2018;28(4):380-389.
27. Ingram J, Johnson D, Copeland M, Churchill C, Taylor H, Emond A. The development of a tongue assessment tool to assist with tongue-tie identification. *Arch Dis Child Fetal Neonatal Ed.* 2015;100(4):F344-F349.
28. Coryllos E, Genna C, Salloum AC. *Congenital Tongue-Tie and Its Impact on Breastfeeding.* Itasca, IL: American Academy of Pediatrics, Section on Breastfeeding; 2004.
29. Ballard JL, Auer CE, Khoury JC. Ankyloglossia: assessment, incidence, and effect of frenuloplasty on the breastfeeding dyad. *Pediatrics.* 2002;110(5):e63.
30. Edmunds J, Miles S, Fulbrook P. Tongue-tie and breastfeeding: a review of the literature. *Breastfeed Rev.* 2011;19(1):19-26.
31. Haham A, Marom R, Mangel L, Botzer E, Dollberg S. Prevalence of breastfeeding difficulties in newborns with a lingual frenulum: a prospective cohort series. *Breastfeed Med.* 2014;9(9):438-441.
32. Iwanaga J, Takeuchi N, Oskouian RJ, Tubbs RS. Clinical anatomy of the frenulum of the oral vestibule. *Cureus.* 2017;9(6):e1410.
33. Hwang YS, Lin CH, Coster WJ, Bigsby R, Vergara E. Effectiveness of cheek and jaw support to improve feeding performance of preterm infants. *Am J Occup Ther.* 2010;64(6):886-894.
34. Flores-Mir C, Korayem M, Heo G, Witmans M, Major MP, Major PW. Craniofacial morphological characteristics in children with obstructive sleep apnea syndrome: a systematic review and meta-analysis. *J Am Dent Assoc.* 2013;144(3):269-277.
35. Katyal V, Pamula Y, Martin AJ, Daynes CN, Kennedy JD, Sampson WJ. Craniofacial and upper airway morphology in pediatric sleep-disordered breathing: systematic review and meta-analysis. *Am J Orthod Dentofacial Orthop.* 2013;143(1):20-30.e23.
36. Huang Y, Quo S, Berkowski JA, Guilleminault C. Short lingual frenulum and obstructive sleep apnea in children. *Int J Pediatr Res.* 2015;1(1).
37. Walsh F, Kelly D. Partial airway obstruction after lingual frenotomy. *Anesth Analg.* 1995;80(5):1066-1067.
38. Genter DJ, Skinner ML, Bailey PJ, Capone RB, Byrne PJ. Airway obstruction after lingual frenulectomy in two infants with Pierre-Robin sequence. *Int J Pediatr Otorhinolaryngol.* 2015;79(9):1592-1594.
39. Caloway C, Hersh CJ, Baars R, Sally S, Diercks G, Hartnick CJ. Association of feeding evaluation with frenotomy rates in infants with breastfeeding difficulties [published online July 11, 2019]. *JAMA Otolaryngol Head Neck Surg.* doi: 10.1001/jamaoto.2019.1696
40. Puapornpong P, Paritakul P, Suksamarnwong M, Srisuwan S, Ketsuwan S. Nipple pain incidence, the predisposing factors, the recovery period after care management, and the exclusive breastfeeding outcome. *Breastfeed Med.* 2017;12:169-173.
41. Kent JC, Ashton E, Hardwick CM, et al. Nipple pain in breastfeeding mothers: incidence, causes and treatments. *Int J Environ Res Public Health.* 2015;12(10):12247-12263.
42. Ngerincham S, Laohapensang M, Wongvisutdhi T, et al. Lingual frenulum and effect on breastfeeding in Thai newborn infants. *Paediatr Int Child Health.* 2013;33(2):86-90.
43. Power RF, Murphy JF. Tongue-tie and frenotomy in infants with breastfeeding difficulties: achieving a balance. *Arch Dis Child.* 2015;100(5):489-494.
44. Buryk M, Bloom D, Shope T. Efficacy of neonatal release of ankyloglossia: a randomized trial. *Pediatrics.* 2011;128(2):280-288.
45. Emond A, Ingram J, Johnson D, et al. Randomised controlled trial of early frenotomy in breastfed infants with mild-moderate tongue-tie. *Arch Dis Child Fetal Neonatal Ed.* 2014;99(3):F189-F195.
46. Hogan M, Westcott C, Griffiths M. Randomized, controlled trial of division of tongue-tie in infants with feeding problems. *J Paediatr Child Health.* 2005;41(5-6):246-250.
47. Berens P, Eglash A, Malloy M, Steube AM, Acad Breastfeeding M. ABM clinical protocol #26: persistent pain with breastfeeding. *Breastfeed Med.* 2016;11(2):46-53.
48. Puapornpong P, Raungrongmorakot K, Mahasitthiwat V, Ketsuwan S. Comparisons of the latching on between newborns with tongue-tie and normal newborns. *J Med Assoc Thai.* 2014;97(3):255-259.

49. Dulong C, Ryce A; Canadian Agency for Drugs and Technologies in Health. *Tongue and Lip Tie Cutting for Posterior Tongue Tie and Lip Tie: Clinical Effectiveness*. Ottawa, Canada: Canadian Agency for Drugs and Technologies in Health; 2019.
50. Ghaheri BA, Cole M, Fausel SC, Chuop M, Mace JC. Breastfeeding improvement following tongue-tie and lip-tie release: a prospective cohort study. *Laryngoscope*. 2017; 127(5):1217-1223.
51. Sethi N, Smith D, Korteque S, Ward VMM, Clarke S. Benefits of frenulotomy in infants with ankyloglossia. *Int J Pediatr Otorhinolaryngol*. 2013;77(5):762-765.
52. Donati-Bourne J, Batool Z, Hendrickse C, Bowley D. Tongue-tie assessment and division: a time-critical intervention to optimise breastfeeding. *J Neonatal Surg*. 2015;4(1):3.
53. Praborini A, Purnamasari H, Munandar A, Wulandari RA. Early frenotomy improves breastfeeding outcomes for tongued-tied infants. *Clin Lac*. 2015;6(1):9-15.
54. Todd DA, Hogan MJ. Tongue-tie in the newborn: early diagnosis and division prevents poor breastfeeding outcomes. *Breastfeed Rev*. 2015;23(1):11-16.
55. Isaiah A, Pereira KD. Infected sublingual hematoma: a rare complication of frenulectomy. *Ear Nose Throat J*. 2013;92(7): 296-297.
56. Sirinoglu H, Certel F, Akgun I. Subacute massive edema of the submandibular region after frenuloplasty. *J Craniofac Surg*. 2013;24(1):e74.
57. Maciag M, Sediva I, Alexander-Scott N. Submandibular swelling and fever following frenulectomy in a 13-day-old infant. *Clin Pediatr (Phila)*. 2016;55(10):990-992.
58. Tracy LF, Gomez G, Overton LJ, McClain WG. Hypovolemic shock after labial and lingual frenulectomy: a report of two cases. *Int J Pediatr Otorhinolaryngol*. 2017;100:223-224.
59. Berry J, Griffiths M, Westcott C. A double-blind, randomized, controlled trial of tongue-tie division and its immediate effect on breastfeeding. *Breastfeed Med*. 2012;7(3):189-193.
60. Braccio S, Chadderton Z, Sheridan A, Upadhyaya M. Tongue-tie division: is it worth it? A retrospective cohort study. *Br J Midwifery*. 2016;24(5):317-321.
61. Dollberg S, Botzer E, Grunis E, Mimouni FB. Immediate nipple pain relief after frenotomy in breast-fed infants with ankyloglossia: a randomized, prospective study. *J Pediatr Surg*. 2006;41(9):1598-1600.
62. Dollberg S, Marom R, Botzer E. Lingual frenotomy for breastfeeding difficulties: a prospective follow-up study. *Breastfeed Med*. 2014;9(6):286-289.
63. Francis DO, Krishnaswami S, McPheeters M. Treatment of ankyloglossia and breastfeeding outcomes: a systematic review. *Pediatrics*. 2015;135(6):E1458-E1466.
64. Geddes DT, Langton DB, Gollow I, Jacobs LA, Hartmann PE, Simmer K. Frenulotomy for breastfeeding infants with ankyloglossia: effect on milk removal and sucking mechanism as imaged by ultrasound. *Pediatrics*. 2008;122(1):E188-E194.
65. Ito Y. Does frenotomy improve breast-feeding difficulties in infants with ankyloglossia? *Pediatr Int*. 2014;56(4):497-505.
66. McGoldrick R, Solari D, Hogan M, et al. Tongue-tie in the newborn: follow-up in the first 6 months. *Breastfeed Rev*. 2016;24(3):33-40.
67. Muldoon K, Gallagher L, McGuinness D, Smith V. Effect of frenotomy on breastfeeding variables in infants with ankyloglossia (tongue-tie): a prospective before and after cohort study. *BMC Pregnancy Childbirth*. 2017;17:1-9.
68. Reading R. Efficacy of neonatal release of ankyloglossia: a randomized trial. *Child: Care, Health and Development*. 2011; 37(6):898-899.
69. Riskin A, Mansovsky M, Coler-Botzer T, et al. Tongue-tie and breastfeeding in newborns-mothers' perspective. *Breastfeed Med*. 2014;9(9):430-437.
70. Sharma SD, Jayaraj S. Tongue-tie division to treat breastfeeding difficulties: our experience. *J Laryngol Otol*. 2015;129(10): 986-989.
71. Srinivasan A, Al Khoury A, Puzhko S, et al. Frenotomy in infants with tongue-tie and breastfeeding problems. *J Hum Lact*. 2019;35(4):706-712.
72. Steehler MW, Steehler MK, Harley EH. A retrospective review of frenotomy in neonates and infants with feeding difficulties. *Int J Pediatr Otorhinolaryngol*. 2012;76(9): 1236-1240.
73. National Institute for Health and Care Excellence. *Division of Ankyloglossia (Tongue-Tie) for Breastfeeding—Guidance (IPG149)*. London, UK: National Institute for Health and Care Excellence; 2005.
74. Daggumati S, Cohn JE, Brennan MJ, Evarts M, McKinnon BJ, Terk AR. Caregiver perception of speech quality in patients with ankyloglossia: comparison between surgery and non-treatment. *Int J Pediatr Otorhinolaryngol*. 2019;119:70-74.
75. Merdad H, Mascarenhas AK. Ankyloglossia may cause breastfeeding, tongue mobility, and speech difficulties, with inconclusive results on treatment choices. *J Evid Based Dent Pract*. 2010;10(3):152-153.
76. Messner AH, Lalakea ML. The effect of ankyloglossia on speech in children. *Otolaryngol Head Neck Surg*. 2002;127(6): 539-545.
77. Klockars T, Pitkaranta A. Pediatric tongue-tie division: indications, techniques and patient satisfaction. *Int J Pediatr Otorhinolaryngol*. 2009;73(10):1399-1401.
78. Mettias B, O'Brien R, Abo Khatwa MM, Nasrallah L, Doddi M. Division of tongue tie as an outpatient procedure: technique, efficacy and safety. *Int J Pediatr Otorhinolaryngol*. 2013;77(4):550-552.
79. Toner D, Giordano T, Handler SD. Office frenotomy for neonates: resolving dysphagia, parental satisfaction and cost-effectiveness. *ORL Head Neck Nurs*. 2014;32(2):6-7.
80. Komori S, Matsumoto K, Matsuo K, Suzuki H, Komori T. Clinical study of laser treatment for frenectomy of pediatric patients. *Int J Clin Pediatr Dent*. 2017;10(3):272-277.
81. Olivi G, Chaumanet G, Genovese MD, Beneduce C, Andreana S. Er,Cr:YSGG laser labial frenectomy: a clinical retrospective evaluation of 156 consecutive cases. *Gen Dent*. 2010;58(3): e126-e133.

82. Puthussery FJ, Shekar K, Gulati A, Downie IP. Use of carbon dioxide laser in lingual frenectomy. *Br J Oral Maxillofac Surg*. 2011;49(7):580-581.
83. Ovental A, Marom R, Botzer E, Batscha N, Dollberg S. Using topical benzocaine before lingual frenotomy did not reduce crying and should be discouraged. *Acta Paediatr*. 2014;103(7):780-782.
84. Shavit I, Peri-Front Y, Rosen-Walther A, et al. A randomized trial to evaluate the effect of two topical anesthetics on pain response during frenotomy in young infants. *Pain Med*. 2017;18(2):356-362.
85. US Food and Drug Administration. Risk of serious and potentially fatal blood disorder prompts FDA action on oral over-the-counter benzocaine products used for teething and mouth pain and prescription local anesthetics. <https://www.fda.gov/drugs/drug-safety-and-availability/risk-serious-and-potentially-fatal-blood-disorder-prompts-fda-action-oral-over-counter-benzocaine>. Published 2018. Accessed August 12, 2019.
86. Mangat AK, Oei JL, Chen K, Quah-Smith I, Schmolzer GM. A review of non-pharmacological treatments for pain management in newborn infants. *Children (Basel)*. 2018;5(10):130.
87. Harrison D, Yamada J, Adams-Webber T, Ohlsson A, Beyene J, Stevens B. Sweet tasting solutions for reduction of needle-related procedural pain in children aged one to 16 years. *Cochrane Database Syst Rev*. 2015;(5):CD008408.
88. Stevens B, Yamada J, Lee GY, Ohlsson A. Sucrose for analgesia in newborn infants undergoing painful procedures. *Cochrane Database Syst Rev*. 2013;(1):CD001069.
89. Meesters N, Simons S, van Rosmalen J, Reiss I, van den Anker J, van Dijk M. Waiting 2 minutes after sucrose administration-unnecessary? *Arch Dis Child Fetal Neonatal Ed*. 2017;102(2):F167-f169.
90. Blass EM, Shah A. Pain-reducing properties of sucrose in human newborns. *Chem Senses*. 1995;20(1):29-35.
91. Kummer AW. Ankyloglossia: to clip or not to clip? That's the question. *ASHA Leader*. 2005;10(17):6-30.
92. Heller J, Gabbay J, O'Hara C, Heller M, Bradley JP. Improved ankyloglossia correction with four-flap Z-frenuloplasty. *Ann Plast Surg*. 2005;54(6):623-628.
93. Lalakea ML, Messner AH, Lalakea ML, Messner AH. Ankyloglossia: the adolescent and adult perspective. *Otolaryngol Head Neck Surg*. 2003;128(5):746-752.
94. Dollberg S, Manor Y, Makai E, Botzer E. Evaluation of speech intelligibility in children with tongue-tie. *Acta Paediatr*. 2011;100(9):e125-e127.
95. Walls A, Pierce M, Wang H, Steehler A, Steehler M, Harley EH. Parental perception of speech and tongue mobility in three-year olds after neonatal frenotomy. *Int J Pediatr Otorhinolaryngol*. 2014;78(1):128-131.
96. Suter VGA, Bornstein MM. Ankyloglossia: facts and myths in diagnosis and treatment. *J Periodontol*. 2009;80(8):1204-1219.
97. Webb AN, Hao W, Hong P. The effect of tongue-tie division on breastfeeding and speech articulation: a systematic review. *Int J Pediatr Otorhinolaryngol*. 2013;77(5):635-646.
98. Messner AH, Lalakea ML. Ankyloglossia: controversies in management. *Int J Pediatr Otorhinolaryngol*. 2000;54(2-3):123-131.
99. Haytac MC, Ozcelik O. Evaluation of patient perceptions after frenectomy operations: a comparison of carbon dioxide laser and scalpel techniques. *J Periodontol*. 2006;77(11):1815-1819.
100. Douglas P, Cameron A, Cichero J, Geddes DT, Hill P, Kapoor V. Australian Collaboration for Infant Oral Research (ACIOR) position statement 1: upper lip-tie, buccal ties, and the role of frenotomy in infants. *Australasian Dental Practice*. Jan/Feb 2018:144-146.
101. Gartner LP, Schein D. The superior labial frenum: a histologic observation. *Quintessence Int*. 1991;22(6):443-445.
102. Bergstrom K, Jensen R, Martensson B. The effect of superior labial frenectomy in cases with midline diastema. *Am J Orthod*. 1973;63(6):633-638.
103. Nakhsh R, Wasserteil N, Mimouni FB, Kasirer YM, Hammerman C, Bin-Nun A. Upper lip tie and breastfeeding: a systematic review. *Breastfeed Med*. 2019;14(2):83-87.
104. Santa Maria C, Aby J, Truong MT, Thakur Y, Rea S, Messner A. The superior labial frenulum in newborns: what is normal? *Glob Pediatr Health*. 2017;4:2333794x17718896.
105. Patel PS, Wu DB, Schwartz Z, Rosenfeld RM. Upper lip frenotomy for neonatal breastfeeding problems. *Int J Pediatr Otorhinolaryngol*. 2019;124:190-192.
106. Jonathan PT, Thakur H, Galhotra A, Galhotra V, Gupta N. Maxillary labial frenum morphology and midline diastema among 3 to 12-year-old schoolgoing children in Sri Ganganagar city: a cross-sectional study. *J Indian Soc Pedod Prev Dent*. 2018;36(3):234-239.